

# Noninvasive Assessment of Breast Pathologies During Pregnancy

Silvana Ojica<sup>1,2</sup>

<sup>1</sup>Faculty of Biomedical Engineering  
“Gr T Popa” University of Medicine and Pharmacy  
Iasi, Romania

Anca Iftemie<sup>1,2</sup>

<sup>2</sup>Faculty of Physics  
“Al. I. Cuza” University  
Iasi, Romania

**Abstract**— The paper is presenting a study regarding the evolution of the mammary gland during the woman pregnancy using the only non-invasive investigation methods: infrared thermography and microwave radiometry. The cell thermogenesis is explored using a thermography method under the conditions of thickness or health, and permits to reveal some affections or the early detection of the risk to pathology status. During pregnancy any exposure to ionizing radiation is forbidden. If a mammary pathology is developed during the pregnancy period, only the thermography and radiometry techniques can be used in order to monitor the mammary glands. Using these methods possible physiological or pathological modifications can be detected. On this study, we found that if the pregnancy is closer to the final delivery date, the breasts temperatures gets higher and the galactofore channels are more pronounced in the IR imaging.

**Keywords**— *noninvasive investigations, mammary gland, microwave radiometry, thermography.*

## I. INTRODUCTION

Regarding cancer detection, the actual research is directed towards discovery of new techniques, other than mammography, which make use of ionogenic penetrating radiations. An answer to this trend would be the application of new measurement techniques, similar in performance with those used in radio-astronomy, applying the laws of body radiation, in the microwaves range [1].

There are two types of methods used to detect the tumour structures, namely non-invasive and invasive methods. The non-invasive methods which make use of the specific domains of the anatomic structure are the infrared thermography and the microwave radiometry.

The invasive methods are those which use the breasts exposure to electromagnetic or magnetic fields, to ultrasounds or to tumour markers (radioactive tracers): the Magneto-mammography, Conventional X ray mammography, Nuclear Tomography and Ductography. The non-invasive methods are preferred, because they do not use ionogenic radiations and can be performed as often as necessary [2].

1) The infrared thermography is a non-invasive method of investigation of the living structure which makes use of the radiation emitted by the biological structure within the infrared range according to the radiation laws of the

electromagnetic spectrum.

2) The microwave radiometry consists in the detection and measurement of the electromagnetic radiation of a certain frequency produced by various physical organisms or biological structures under normal or pathological conditions. This emission occurs according to the laws of radiation. The intensity of the radiation changes with the body temperature. The microwaves have a higher wavelength and are less absorbed by the tissue traveled from the tumour to the surface [3].

Physical changes of the body during pregnancy. The physical modifications during pregnancy are also associated with pregnancy symptoms or signs. Most of the changes occurring during the first trimester are named symptoms, while those which occur during the two trimesters are signs specific to pregnancy. The most frequent physical transformations that can be experimented during pregnancy are: absence of menses, morning nauseas, pronounced fatigue condition, cephalalgia, modifications and leaks at the breasts level, frequent urination, constipation, dyspnoea, Braxton Hicks contractions, affections of gum and teeth, skin affections specific to pregnancy, cramps at the level of inferior abdomen, dizziness, nauseas, back pains, eyesight alterations, increasing heart pulse, problems with blood circulation, affection of the respiratory tract [3].

3) Blood circulation during pregnancy

The blood circulation during pregnancy gets quite difficult due to the changes in the organism. The hemorrhoids, kinks, feet swallowing or varicosity can cause more troubles. During the last two pregnancy trimesters, the feet kinks are the most frequent circulation problems [1].

4) Breasts in pregnancy and hazard of breast cancer

The breasts modify very much during pregnancy and the specific modifications can be easily mistaken for breast malign tumour. The first sign of breast cancer during pregnancy, which must be first investigated, is that in which the nodules feel painful at breast level.

Medics assert that, as a rule, the cancer cells appear at pregnant women between the 32-38 weeks of pregnancy. This is the period of maximum hazard! During the pregnancy, the breasts modify based on the hormonal changes which occur.

That is why it is considered that there is a higher risk than usually for the cancer cells to appear at their level. If there is

also a personal history, with first rank relatives who suffered from breast cancer, the chances increase even more. The surviving rate in women who suffer from breast cancer during pregnancy does not appear to be affected, as compared to that in women who manifest the disease outside pregnancy. The specialists maintain that this type of cancer detected in pregnancy does not seem to affect the fetus in any aspect. The cancer cell at the breast level does not pass from mother to fetus [2].

#### 5) Breast cancer treatment in pregnancy

The earlier the treatment is administrated in the incipient phase, the higher are the curing and surviving chances. Generally, the treatment application during pregnancy is not recommended. Usually, this implies chemotherapy and tamoxifen, both extremely dangerous during pregnancy. They can irremediably affect the fetus, the congenital malformations being the most risky [4]. The only safe method to treat the breast cancer in pregnancy is the surgical intervention, namely the mastectomy, but this is a hard decision to take. As a rule, the medics recommend it if: cancer tumour is very big, there are several types of cancer at the breast level, in order to avoid cancer recurrence at the same breast [4-11].

## II. WORKING METHOD

The subject was investigated using two types of functional methods: the microwave radiometry and the IR thermography.

#### A. IR thermograph

The obtained images are the result of the reception of the infrared radiations emitted by the superficial cutaneous zones of the body. The thermograph used in this study was of ThermoCam B2 type.

#### B. Microwave radiometer

The obtained images are the result of the reception of the microwaves emitted by the cutaneous and sub-cutaneous zones of the body. During this study we used a RTM-01-RES radiometer. In order to obtain the breast thermal image, the subject was seated with the uncovered thorax, her hands on the hips, for 20 minutes, to facilitate the heat exchange and heat balance with the environmental temperature which was of  $(23-24)^{\circ}\text{C}$ . The thermal and radiometric images were taken three minutes from each other, under the same conditions of surrounding temperature.

The subject was investigated using two types of functional methods: the microwave radiometry and the IR thermography.

## III. RESULTS

The voluntary subject was clinically healthy, thermographically and radiometrically evaluated during the period preceding the pregnancy. The control measurement before pregnancy was carried out in the first day of ovulation, a raised and uniform temperature of the both breasts being noticed (Fig. 1).

The maximum temperature recorded during the ovulation period gradually diminishes until the end of the first trimester of pregnancy, when the apparition of placenta as an organ, and the hormones secreted by this begin to produce a slow heating of the mammary tissue that commence to develop.

During this period, one can notice the increase of the temperature, size and sensitivity of the mammary glands, these data being correlated with those from the specialized recording devices.

Even though the breasts start to develop at puberty, the glandular tissue which produces the lactation is only developed completely during pregnancy. As the level of estrogen, progesterone and other hormones specific to pregnancy increases, the breasts modifies, preparing from the very first trimester of pregnancy to secrete milk for the baby.

They increase in volume and their sensitivity when touched is increasing, while the venous network is more evident and becomes visible through the tegument. These modifications are much more pronounced at women expecting for the first time, since the mammary glands completely develop after giving birth for the first time. Repeated explorations were carried out to identify the temperature distribution at the level of mammary gland during at 39 weeks (Fig. 2 - 5).

During ovulation and immediately after the moment of conception of the fetus, because of the hormones secreted by the organism, the breast temperature is slightly over the normal level. During the first two trimesters of pregnancy the organisms focuses its entire energy on the harmonious development of the fetus.

Immediately after birth – and here we talk about a natural birth – the lactate secretion appears (Fig. 6).

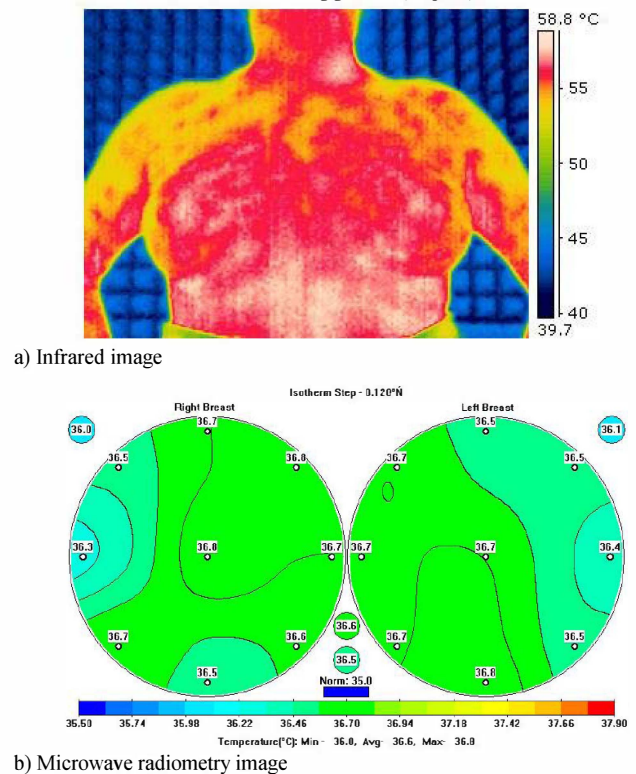
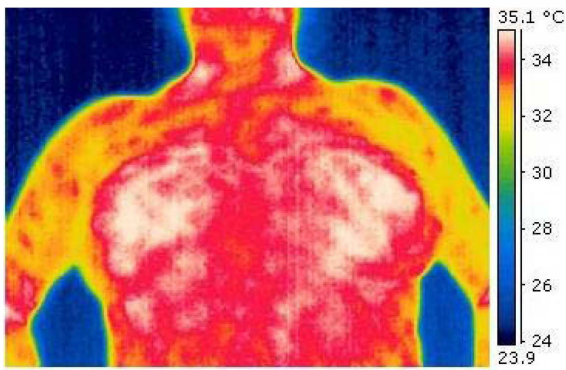
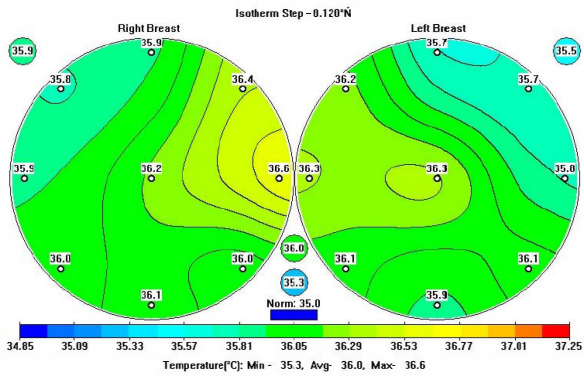


Fig. 1. Temperature distribution (control measurement).



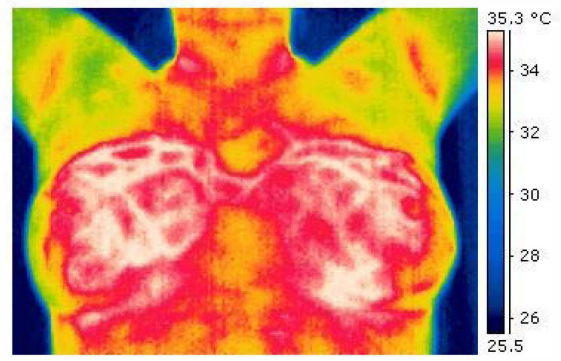


a) IR image

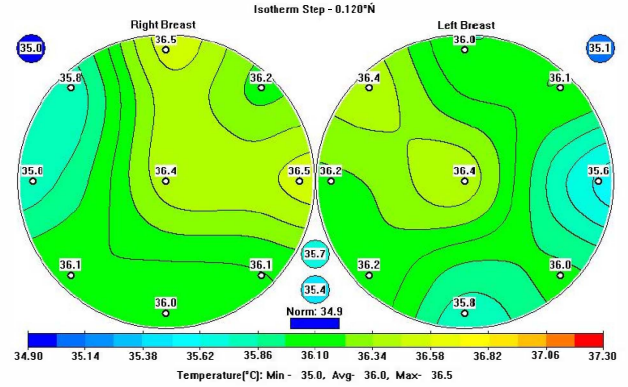


b) Microwave radiometry image

Fig. 2. Temperature distribution at the level of mammary gland (8 weeks).

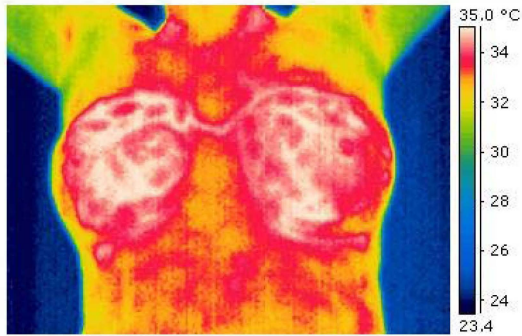


a) IR image

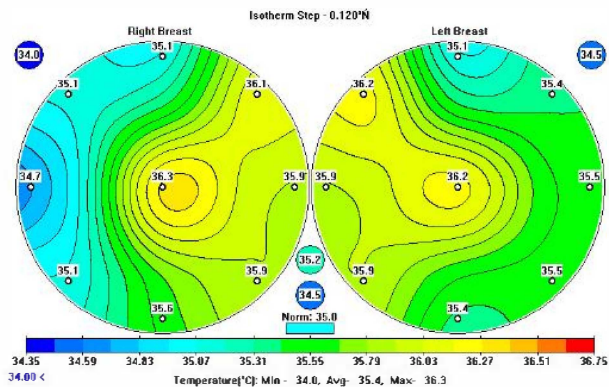


b) Microwave radiometry image

Fig. 4. Temperature distribution at the level of mammary gland (29 weeks).

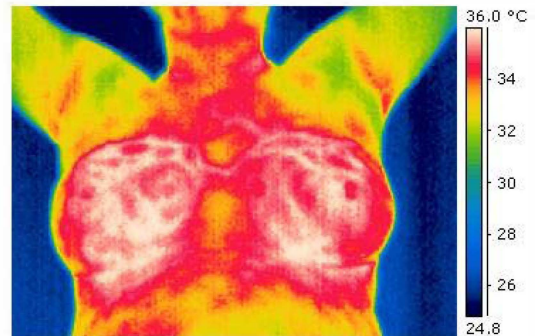


a) IR image

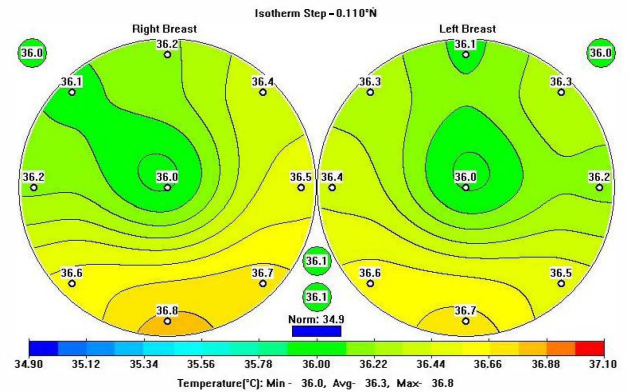


b) Microwave radiometry image

Fig. 3. Temperature distribution at the level of mammary gland (18 weeks).

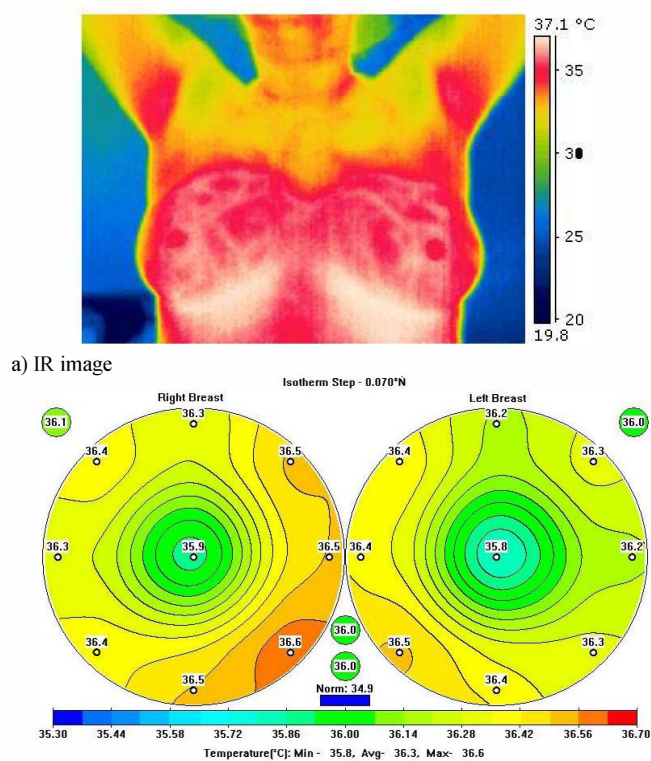


a) IR image



b) Microwave radiometry image

Fig. 5. Temperature distribution at the level of mammary gland (39 weeks).



b) Microwave radiometry image  
Fig. 6. Temperature distribution at the level of mammary gland (4 weeks after pregnancy).

This sudden change leads to an increase of the breast temperature and the presence of breast milk in the mammary glands and the galactophore channels for a longer period of time leads to their inflammation.

Thus, by using the thermo-vision methods one may observe the areas that are predisposed to mastitis, which appears in case of an incomplete elimination of the breast milk.

#### IV. CONCLUSION

The infrared thermography and the microwave radiometry are the only methods that permit to monitor the mammary glands during pregnancy, allowing the detection of possible physiological or pathological alterations.

Following the performed explorations, one can notice a temperature variation of about 1°C as reported to week zero, and an increase of the mammary glands size and sensitivity.

During the 18-th week, one can notice the minimum point detected during pregnancy, then a uniform temperature raise the breast temperature and the more pronounced the galactophore channels in the thermographic imaging (Fig. 7). The more advance the pregnancy period is, the higher it is the breast temperature and the more pronounced the galactofore channels in the thermographic imaging.

By using the Microwave radiometry and the Infrared thermography one may determine – in a non invasive and non ionized manner – whether at the level of the mammary gland there are temperature changes that can lead to an inflammation of the tissue.

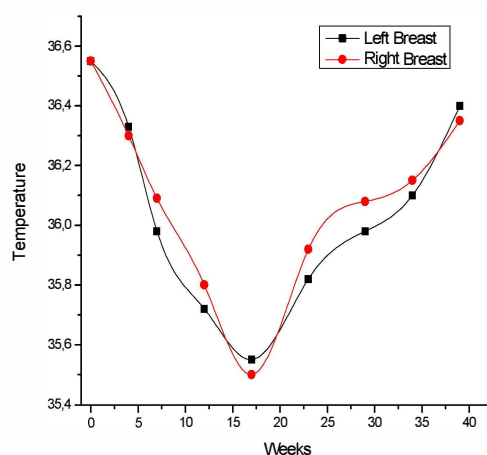


Fig. 7. Evolution of the mammary gland temperature.

Taking into account that during pregnancy and breast feeding period the investigations that may affect the fetus are completely forbidden, these two methods are the only that can be used without any risk.

This study is one of its kind and it underlined the modifications of the mammary gland during pregnancy.

#### ACKNOWLEDGMENT

This work was supported by Autoritatea de Management pentru Programului Operațional Sectorial Dezvoltarea Resurselor Umane 2007-2013 Grant RO08- POSDRU-6/1.5/S/25 „Dezvoltarea oportunităților oferite doctoranzilor pentru traiectorii flexibile în carieră”.

#### REFERENCES

- [1] Munteanu I., *Obstetric book (Tratat obstetrica)*, Editia a II-a, Editura Academiei Romane, 2006, Bucuresti.
- [2] Ch. Zanoschi, *Gynecological anatomy book (Tratat de anatomie ginecologica)*, Ed. Scripta Manent, Iasi, 2004.
- [3] O. Baltag, A. Banarescu, D. Costandache, M. Rau, S. Ojica, “Microwaves and Infrared Thermography – Applications in Early Breast Cancer Detection”, *International Conference on Advancements of Medicine and Health Care through Technology, IFMBE Proceedings Volume 26*, 2009, pp 195-198.
- [4] S. Standing, *Grey's Anatomy*, Ed. Elsevier Churchill Livingstone, London, 2005.
- [5] L. Miron, E. Bild, *Cancer Therapy (Terapia cancerului)*, Ed. Tehnopolis, 2003, Iasi.
- [6] Anbar M., Breast Cancer, *Quantitative Dynamic Telethermometry in Medical Diagnosis and Management*. CRC Press, Ann Arbor, Mich, pp.84-94, 1994.
- [7] Gamagami P., “Indirect signs of breast cancer: Angiogenesis study.” *Atlas of Mammography*, Cambridge, Mass., Blackwell Science pp.231-26, 1996.
- [8] Gautherie M., Albert E., Keith L., *Thermal Assessment of Breast Health*, MTP Press Ltd.
- [9] Sterns E.E., Zee B., Sen Gupta J., and Saunders F.W., “Thermography: Its relation to pathologic characteristics, vascularity, proliferative rate and survival of patients with invasive ductal carcinoma of the breast.” *Cancer* 77:1324-8, 1996.
- [10] Head J.F., Wang F., Elliott R.L., *Breast thermography is a noninvasive prognostic procedure that predicts tumor growth rate in breast cancer patients.*, *Ann N Y Acad Sci* 698:153-158, 1993.
- [11] Head J.F., Elliott R.L., *Breast Thermography*. *Cancer* 79:186-8, 1995.